

Treatment of an edentulous space with a digital workflow

Two-piece ceramic implants in the aesthetic zone

Prof. Heinz Kniha, Thomas Lassen & Dr Kristian Kniha, Germany

More and more dentistry students, individuals working in dental care, dental science and dental technology, as well as university lecturers, are now encountering modern zirconia implants. The subject of zirconia implants not only polarises patients, but is also hotly debated at international congresses and in respected scientific publications. Irrespective of this, the amount of evidence-based *in vivo* data concerning zirconia implants continues to grow. On the one hand, the ceramic surface allows a very pleasing aesthetic result to be achieved, especially in the soft-tissue region. Studies with a follow-up period of three years have shown that hard tissue remains stable

and that there is even a statistically significant enlargement of the interdental papillae.¹⁻³ On the other hand, an experimentally induced mucositis study has shown that titanium implants prompt a greater inflammatory immune response to plaque accumulation with regard to specific inflammatory markers (interleukin-1 beta values, total bacterial count and sample volumes of *Tannerella forsythia* and *Prevotella intermedia*).^{4,5} These clinical insights into zirconia implants lead us to hope that the risk of peri-implantitis too can be minimised with the lower incidence of mucositis. Initially, single-piece zirconia implants were restored with cement-retained prostheses.

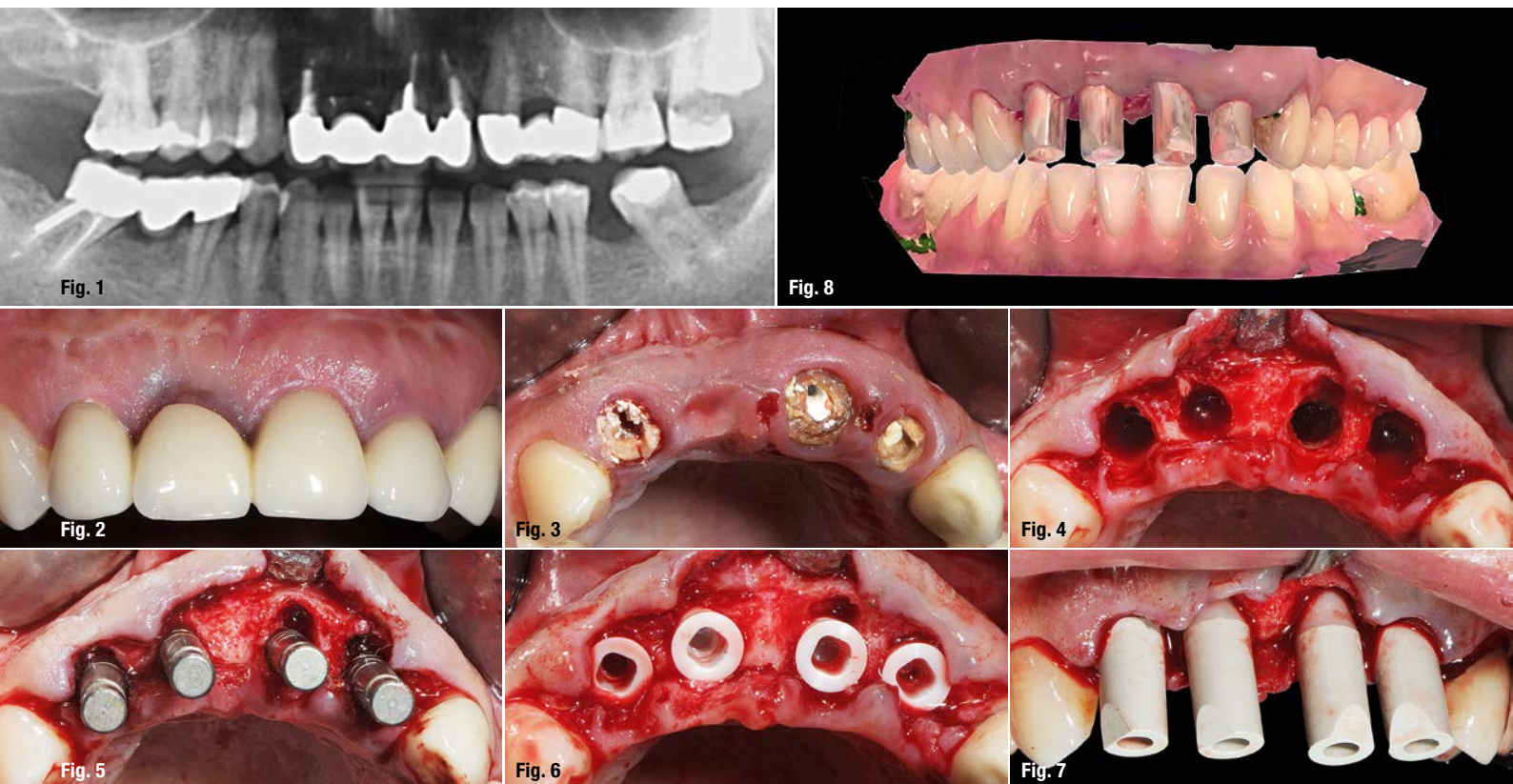


Fig. 1: Radiographs showing root fillings and post-and-cores in teeth #12, 21 and 22. **Fig. 2:** Visible scarring after apicectomy and dark-coloured gingiva in region #11. **Fig. 3:** Secondary caries in the hopeless abutment teeth. **Figs. 4-6:** Immediate implantation of two-piece zirconia implants in regions #12, 11, 21 and 22. **Figs. 7 & 8:** An intra-op digital impression of the two-piece implants was taken.

Now, two-piece implants allow screwed connections between the prosthesis and implants. The following case describes the clinical application of two-piece zirconia implants in an extensive anterior reconstruction in combination with digital procedures.

Patient case

Baseline

This is a clinical case of a 34-year-old healthy woman. The baseline showed a splinted bridge extending from tooth #12 to tooth #22, where tooth #11 had been replaced with a bridge unit. Radiographs showed root fillings and post-and-cores in teeth #12, 21 and 22 (Fig. 1). Scarring after apicectomy and dark-coloured gingiva in region #11 were noted (Fig. 2). Clinically, there was a loosened bridge with secondary caries in the hopeless abutment teeth (Fig. 3). The procedure was explored with the patient and the various treatment options were discussed. The patient wanted a permanently fixed restoration for which the healthy adjacent teeth in positions #14 and 13 should not be ground down. With this in mind, to close the gap, four zirconia implants restored with screw-retained crowns with palatal screw access holes was agreed with the patient. The patient exhibited excellent oral hygiene. All conditions for immediate im-

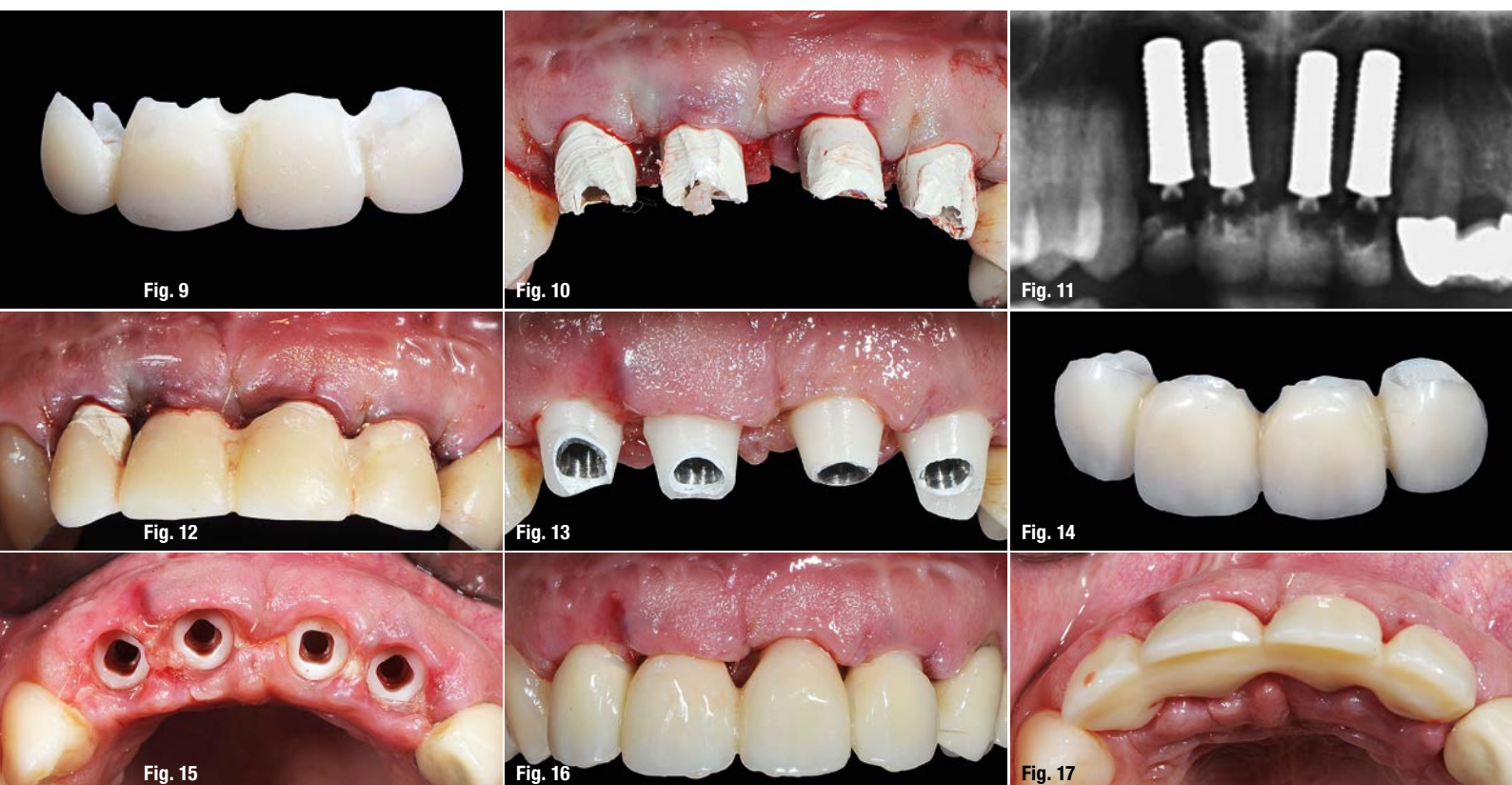
plantation with immediate treatment (without immediate loading) were met.

Surgical procedure

A pickup impression was taken so that chairside temporary restorations could be produced after the implantation. First, teeth #12, 21 and 22 were extracted atraumatically. After tooth extraction, the situation was not inflamed and there was sufficient bone available to allow immediate implantation of two-piece zirconia implants (PURE implants, with the ZLA surface, Straumann) in regions #12, 11, 21 and 22 while maintaining primary stability (Figs. 4–6). This was achieved with a minimally invasive approach via a marginal incision without vestibular release. Scan bodies allowed an intraoperative digital impression of the two-piece implants to be taken (TRIOS 3, 3Shape; Figs. 7 & 8). The digital data set was then sent via the Internet to the laboratory to produce temporary crowns.

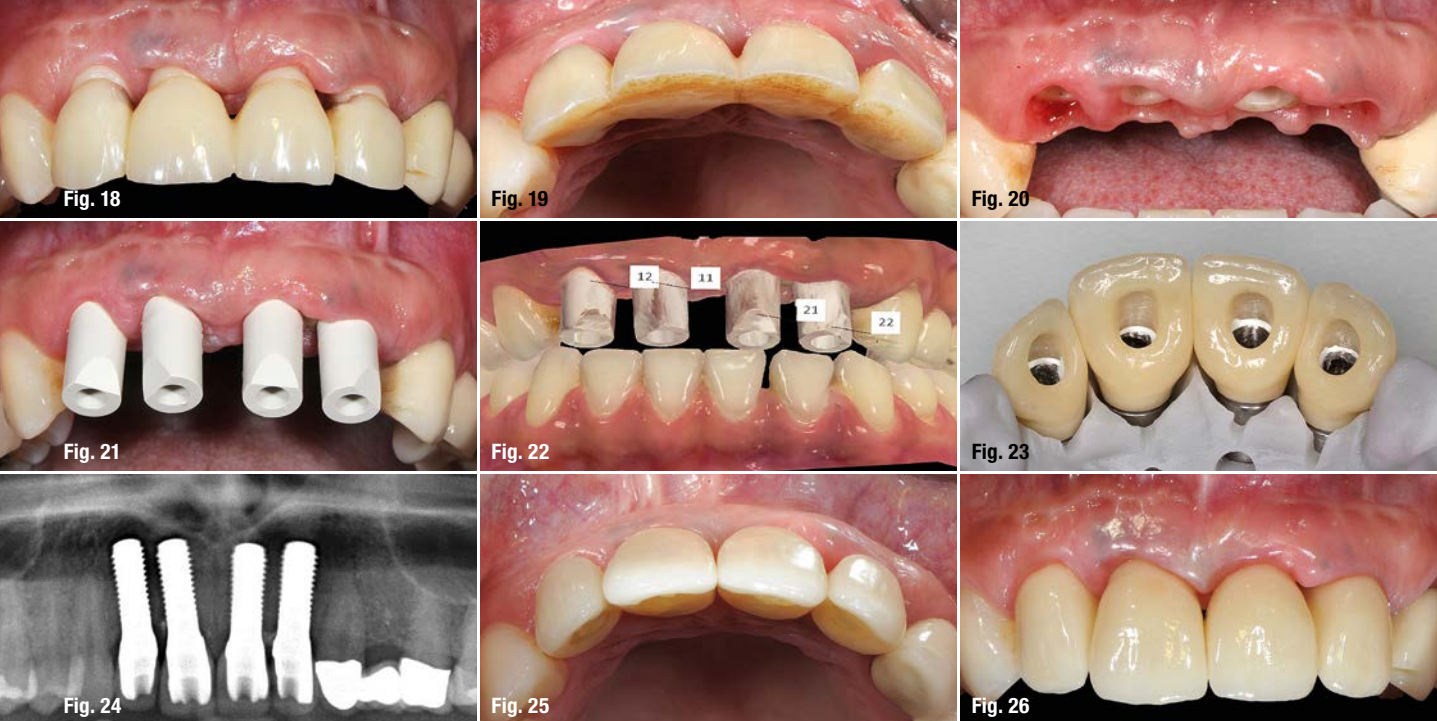
Prosthetic restoration

Wound closure was performed with single interrupted sutures. All scan bodies were shortened and transformed into provisional telescopic solutions. The temporary crowns were made with Luxatemp (DMG Chemisch-Pharmazeutische Fabrik) based on the existing pickup



Figs. 9–12: The temporary crowns, which were made based on the existing pickup impression, were provisionally cemented to the anchoring elements.

Figs. 13–17: Clinical situation at the second appointment seven days after the implant surgery. The dental restorations were produced by the Thomas Lassen dental laboratory.



Figs. 18–22: Another digital impression of the intra-oral situation was taken. **Fig. 23:** The definitive implant prostheses. **Figs. 24–26:** The radiographic and clinical situation six weeks post-op.

impression. These were then provisionally cemented to the anchoring elements with Temp-Bond (Kerr Dental, Figs. 9–12). During the cementing process, it was essential that no material was pressed into the periodontal gap. Postoperative radiographic follow-up was performed in line with the cementation protocol (Fig. 11). The temporary restorations were taken out of occlusion, and the patient was instructed not to bite off food with her incisors in the next three months, but rather to spread the masticatory force to the posterior region.

All the dental restorations were produced by the Thomas Lassen dental laboratory (Figs. 13–17). The sutures were removed as standard on the seventh day postoperatively. In the same appointment, the chairside temporary restorations were replaced with aesthetically high-quality temporary restorations made of composite in the form of a crown block. Provisional bonding was achieved with Temp-Bond on the screw-retained zirconia mesostructures. After a total healing phase of three months, there was a significant harmonisation of the soft-tissue situation. Another digital impression of the intra-oral situation was taken so that the final crowns could be produced (Figs. 18–22). The CAD/CAM-supported workflow allows simple and time-saving procedures using modern materials. The definitive implant prostheses consisted of screw-retained customised CAD/CAM-milled zirconia frameworks which were bonded with the angled Variobase abutments in the laboratory and then veneered (Fig. 23). The radiographic and clinical situation six weeks after implantation showed stable bone progression and irritation-free, pale membranes (Figs. 24–26).

Conclusion

Two-piece zirconia implants allow reliable anterior reconstruction with predictable outcomes. The individual

soft-tissue conditioning can start directly after implantation. The digital workflow in particular supports the optimum shaping of the peri-implant soft tissue with ceramic materials and accelerates interdisciplinary processes. It is evident that there is an increase in the size of the interdental papillae in the first three years. For this reason, the interdental spaces should be physiologically designed from the outset as part of the prosthetic treatment.



about the author



Prof. Heinz Kniha is a Munich-based oral surgeon working in a joint practice together with Dr Karl Andreas Schlegel. He is highly specialised in implant dentistry and is an internationally prominent figure in research on zirconia implants. He studied dentistry and human medicine at the Friedrich-Alexander-University Erlangen-Nürnberg and University

Hamburg, and completed his education as a specialist in maxillofacial surgery under the supervision of Prof. Dieter Schlegel at the Medical Center of the University of Munich. Today, being the author of many scientific articles, he is frequently invited to lecture at dental conferences on an international level.

contact

Prof. Dr Dr Heinz Kniha
 Arnulfstraße 19 (Renaissancehaus)
 80335 Munich, Germany
 Phone: +49 89 590686990
 www.prof-kniha-kieferchirurgie.de

